

Pancreas Divisum and acute
relapsing pancreatitis
Tricks for selecting the right
patient

Jacques.deviere@erasme.ulb.ac.be
Erasme University Hospital,
ULB, Brussels
Belgium

Definition

- Recurrent episodes of pancreatitis occurring in a setting of a normal morpho-functional gland.
- Is Pancreas Divisum a normal morphology?

– Testoni, PA JOP (online) 2001; 2: 357-367.

Pancreas Divisum

- Incidence: 5-10% in western populations
- Incidence of pancreatitis (any causes): 0.1%
- Conflicting results of ERCP's based studies mainly linked to recruitment biases
- Endoscopic access more difficult, no more ERCP related complications
- MRCP clarified the problem, atleast in Europe?

Role of imaging

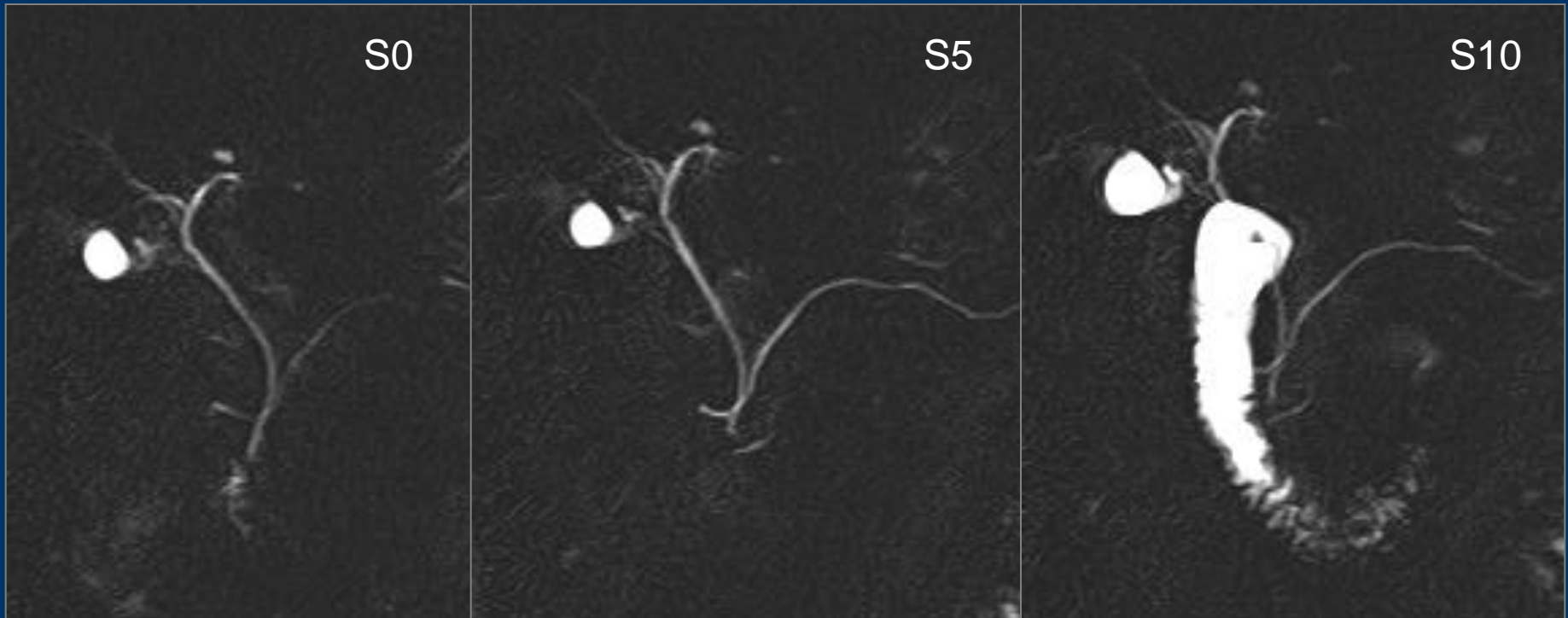
- Detect a mechanical factor that may induce a transient obstruction to pancreatic juice outflow.
- Define anatomy
- Detect the consequences of decreased parenchymal compliance associated with CP
- Be non invasive

- MRCP with secretin stimulation

Detailed morphology of the ducts without risks

Secretory response, compliance and resistance to outflow

S-MRCP and Pancreas divisum



Normal response to
stimulation

P divisum and pancreatitis

| | <u>N Patients</u> | <u>PD %</u> | |
|---------|-------------------|-------------|------|
| P > 0.2 | RAP | 67 | 10.4 |
| | Enzymes | 42 | 11.9 |
| | Recurrent pain | 48 | 12.5 |
| | Severe CP | 68 | 8.8 |
| | Controls | 54 | 11.1 |
| | Total | 279 | 10.8 |

P = 0.94

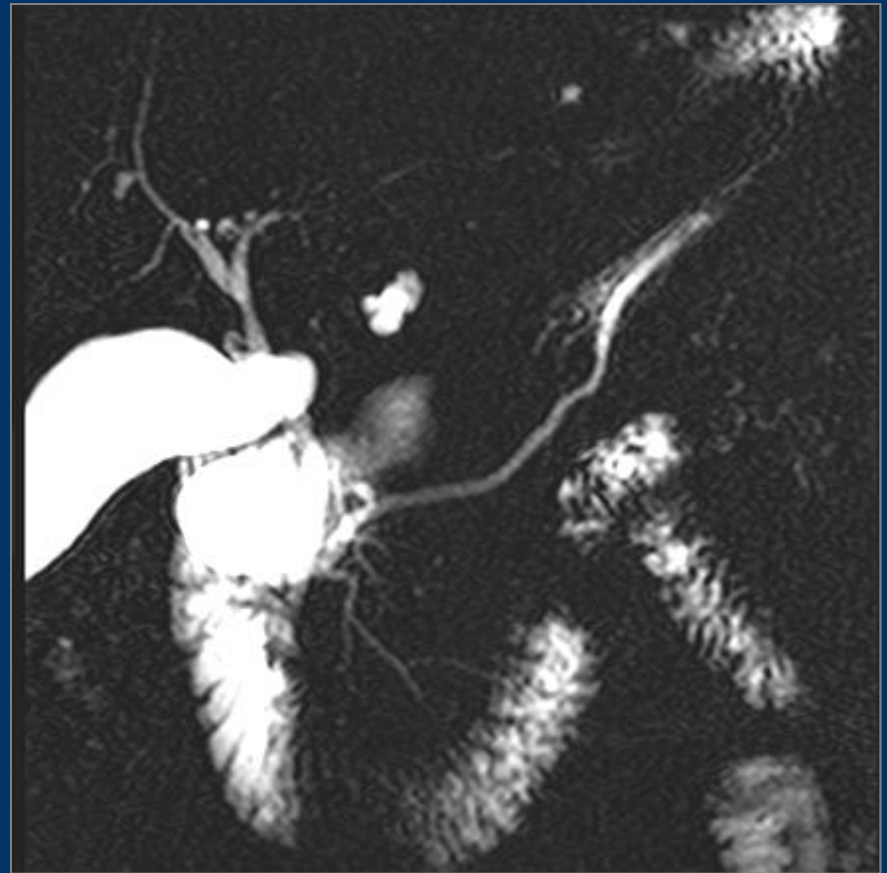
Pancreas divisum and pancreatitis

N = 279

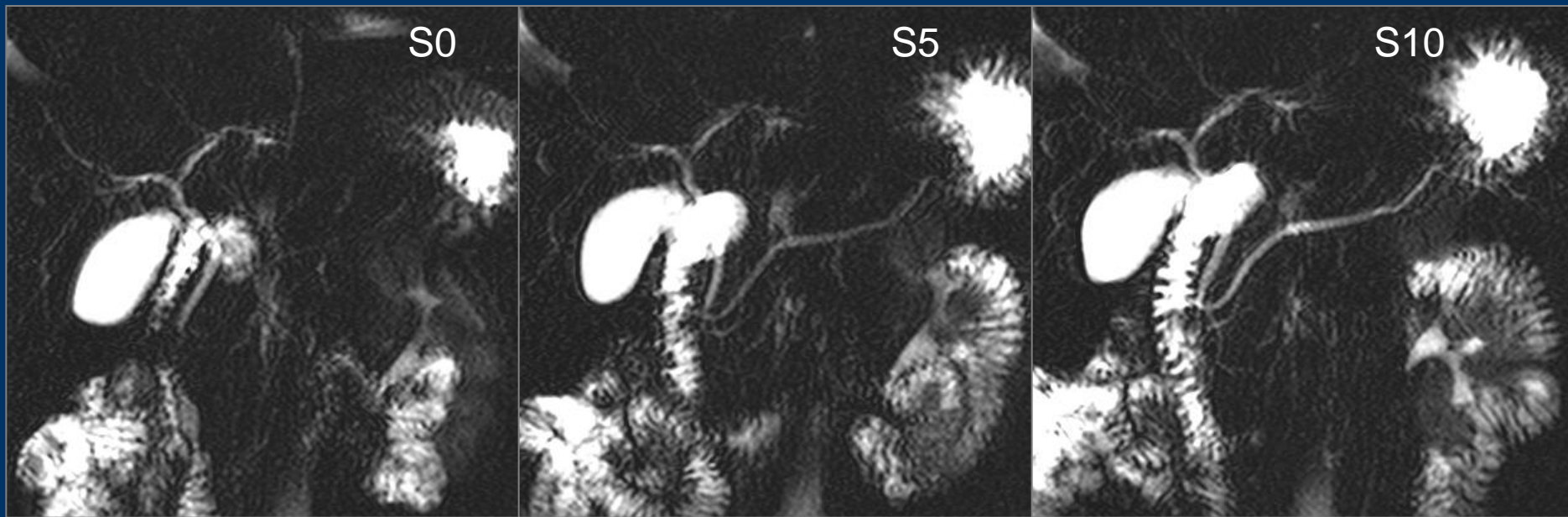
| | Abnormal non PD | Abnormal PD |
|----------|--------------------|----------------|
| ARP | 11.6% | 14.3% * |
| Enzymes | 16.2% | 0% |
| Pain | 7.1% | 0% |
| Controls | 2.1% | 0% |

* $p = 0.41$

Gastrointest Endosc 2001;53:728-33



Pancreas divisum



Abnormal response to stimulation
Dorsal duct remains enlarged

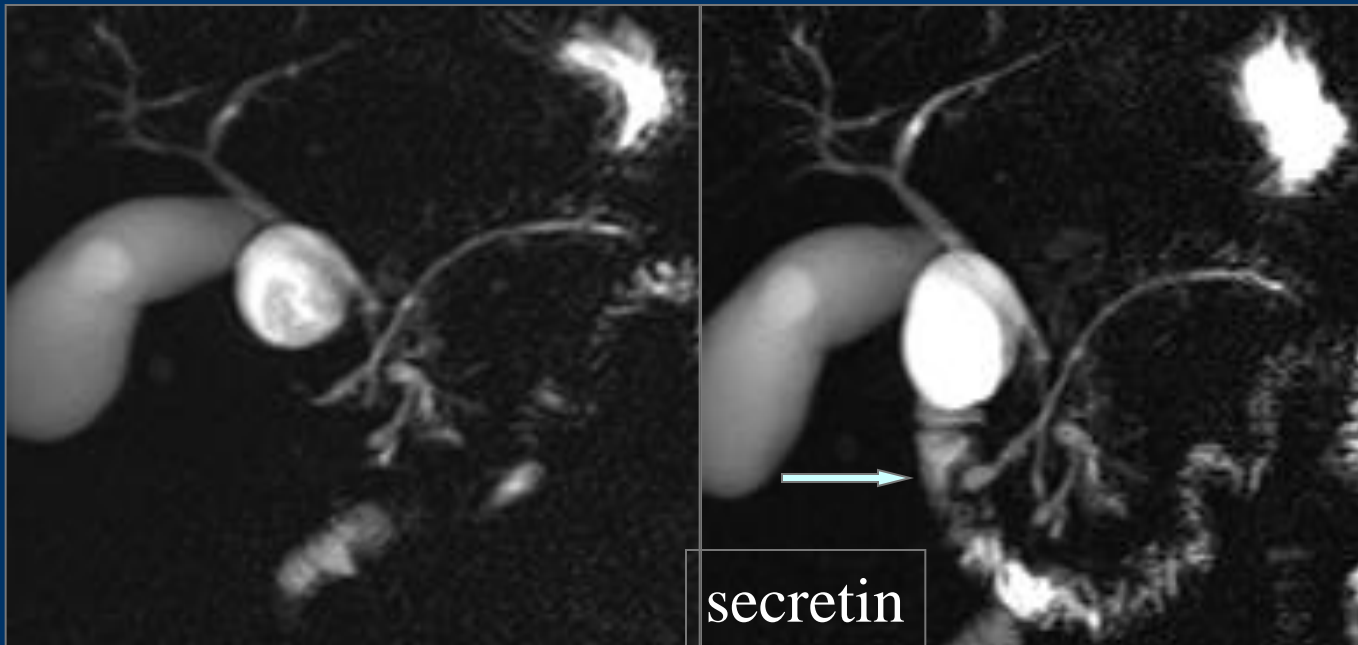
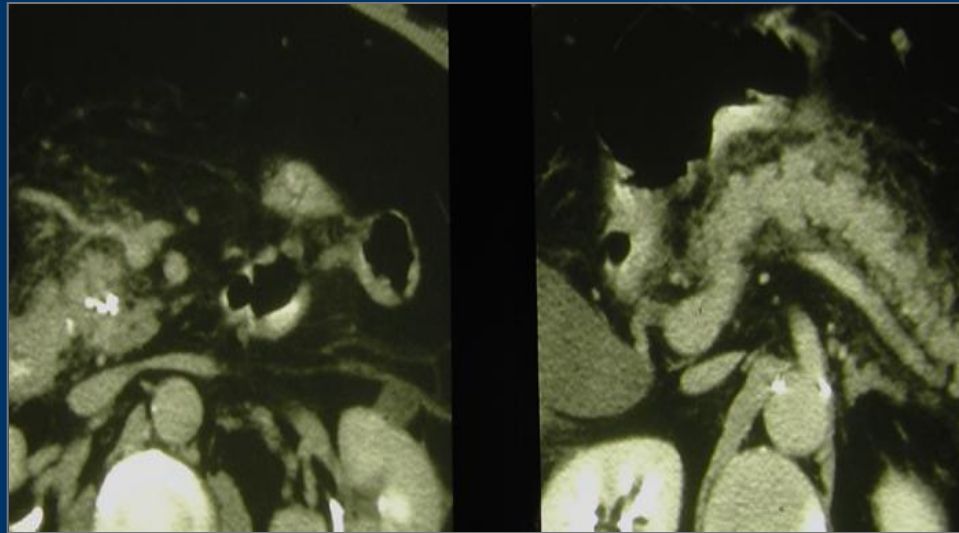
S-MRCP vs pancreatic SOM

Pancreatic SO manometry

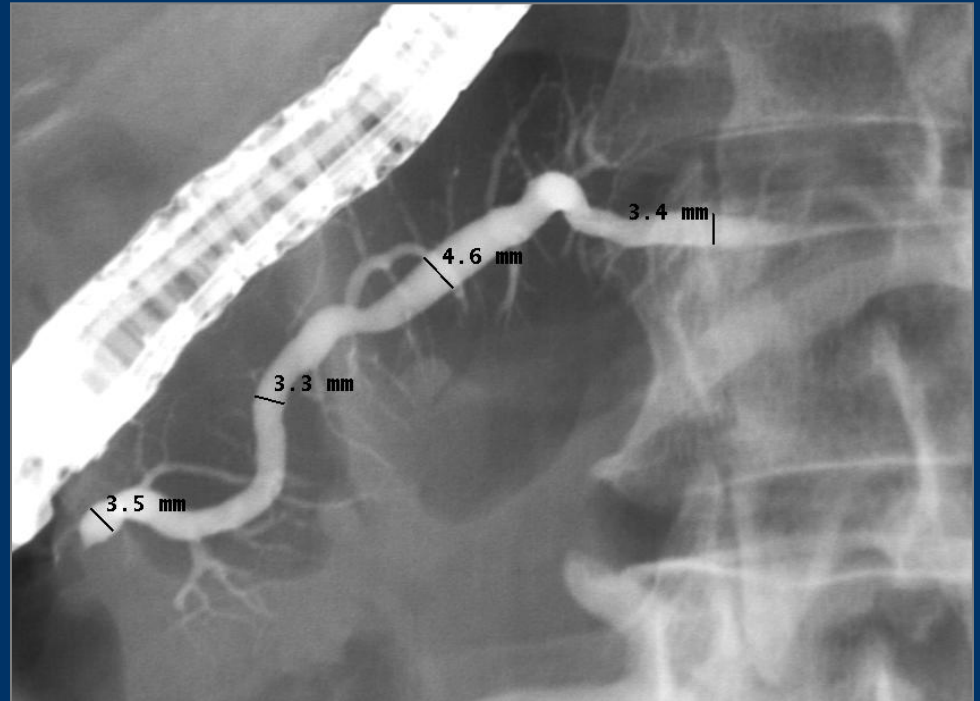
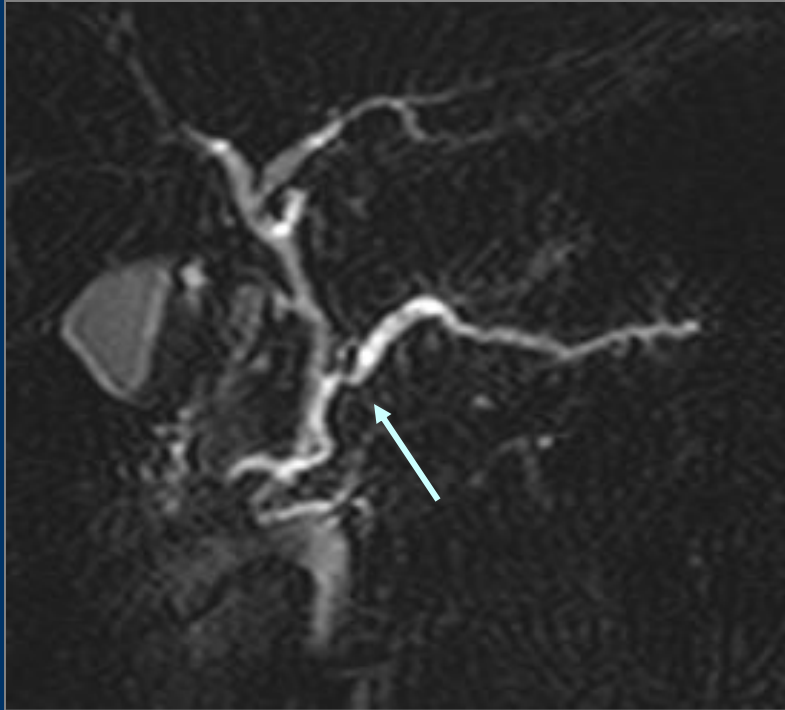
| | | Normal | | Abnormal |
|---------------|----------|--------|---|----------|
| <u>S-MRCP</u> | Normal | 11 | 9 | 2 |
| | Abnormal | 4 | 0 | 6 |

S-MRCP and pancreatic SOM concordant in 13/15 patients

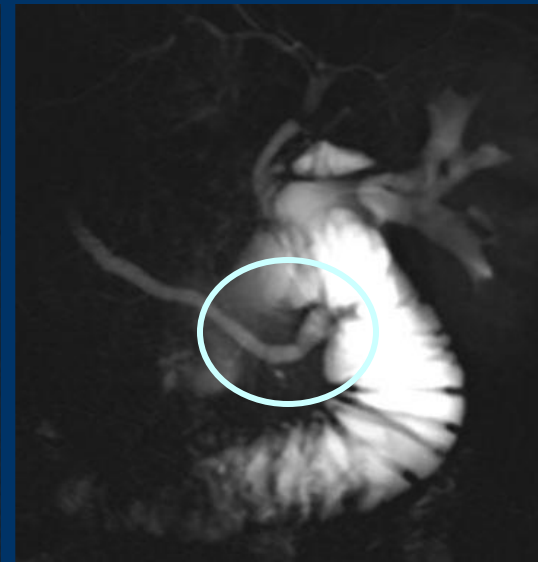
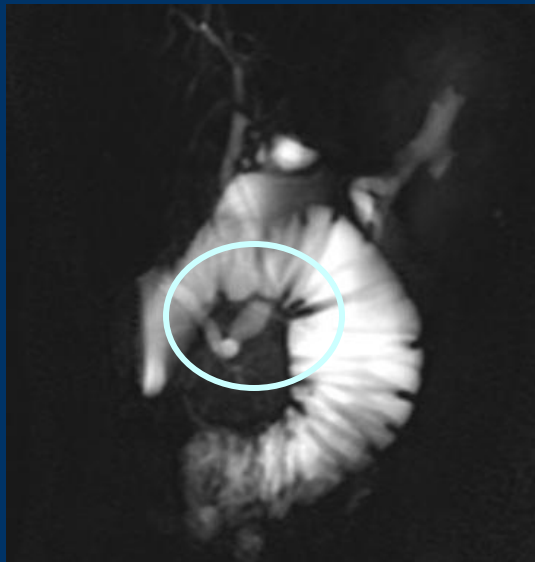
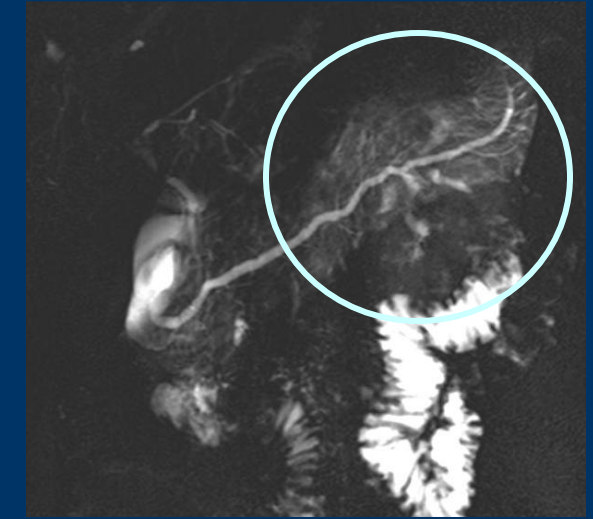
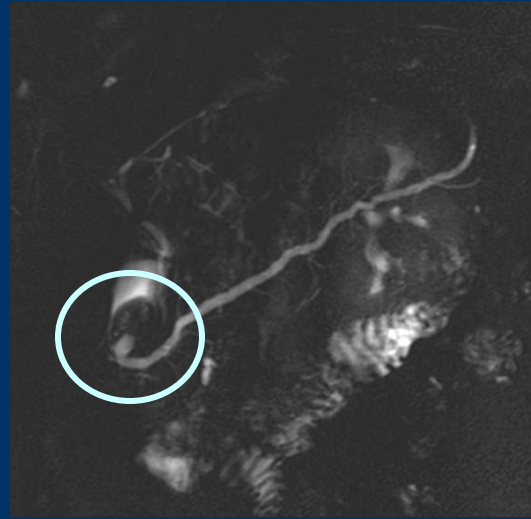
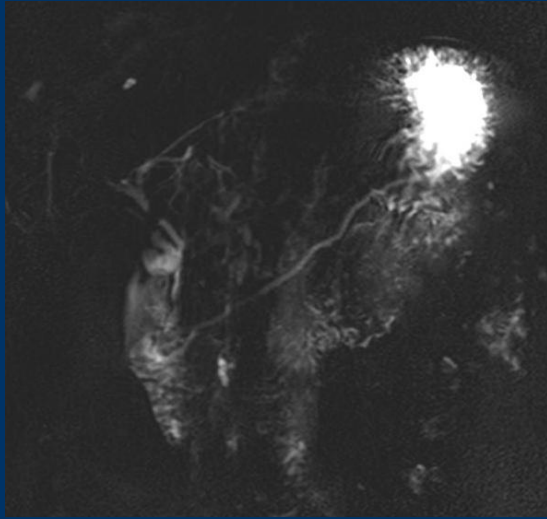
P divisum, chronic and acute pancreatitis santorinicele



S-MRCP vs ERCP



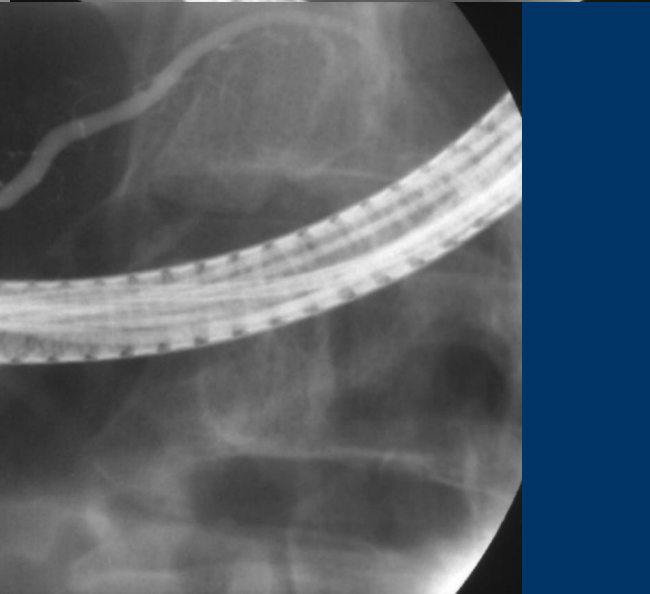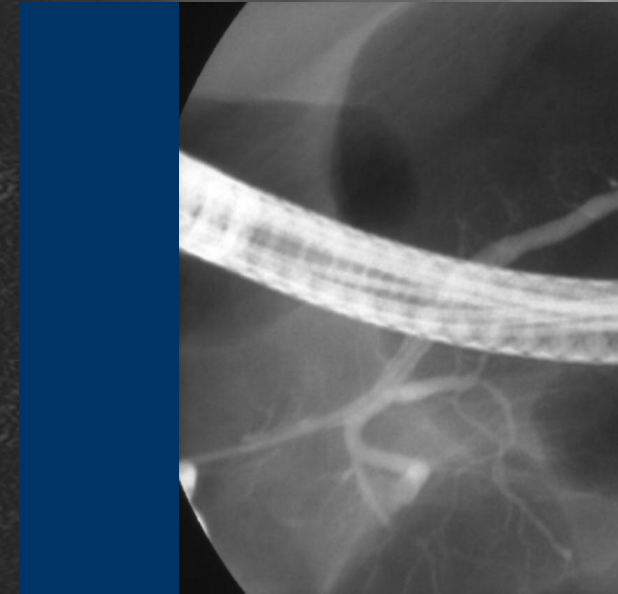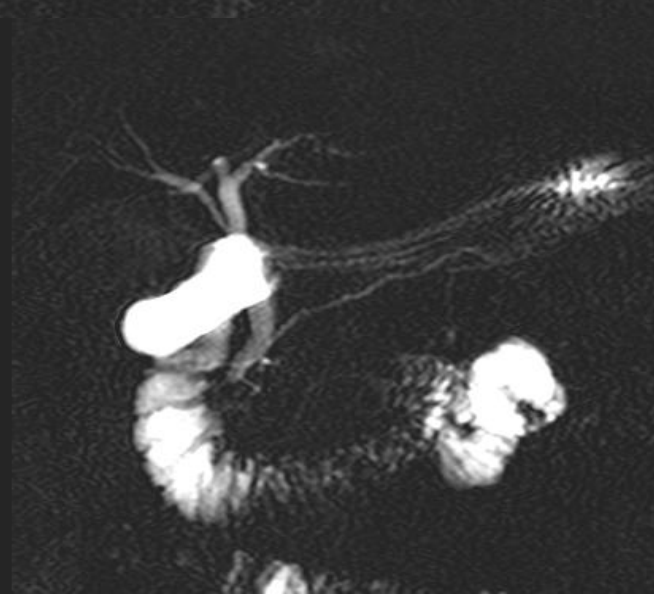
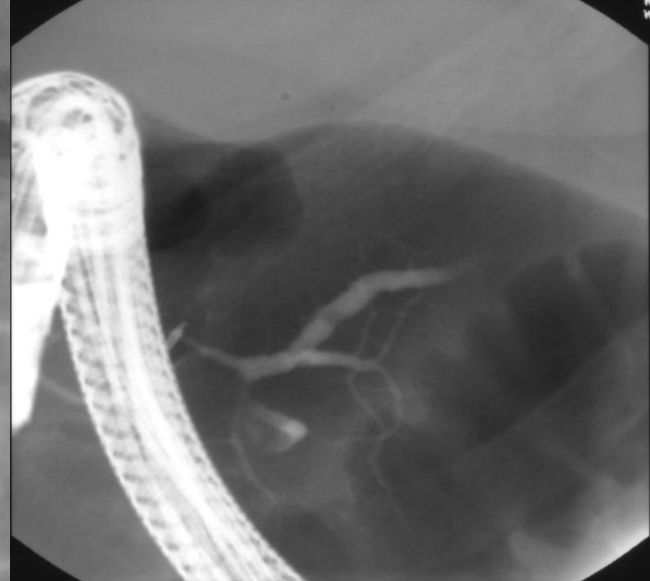
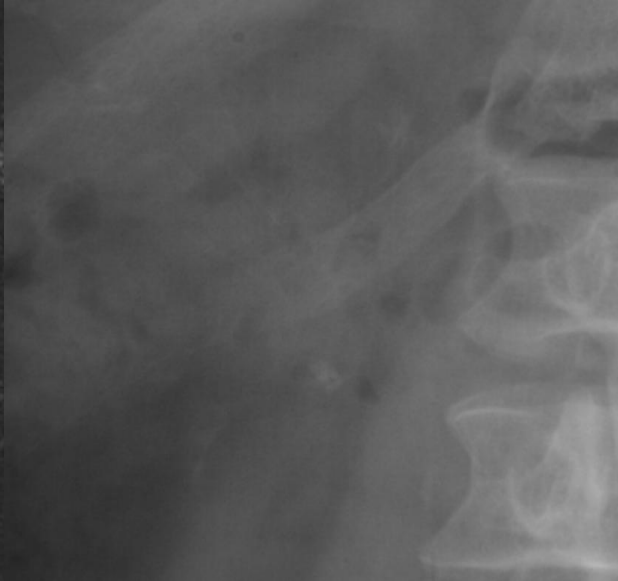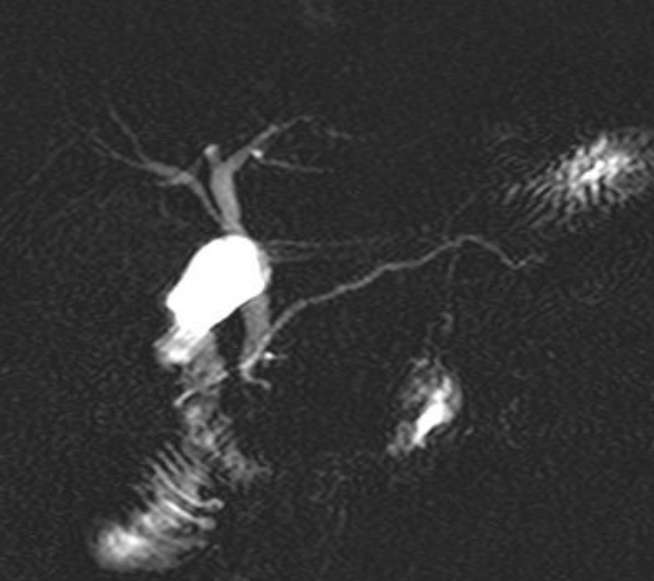
P divisum, santorinicele, parenchymography

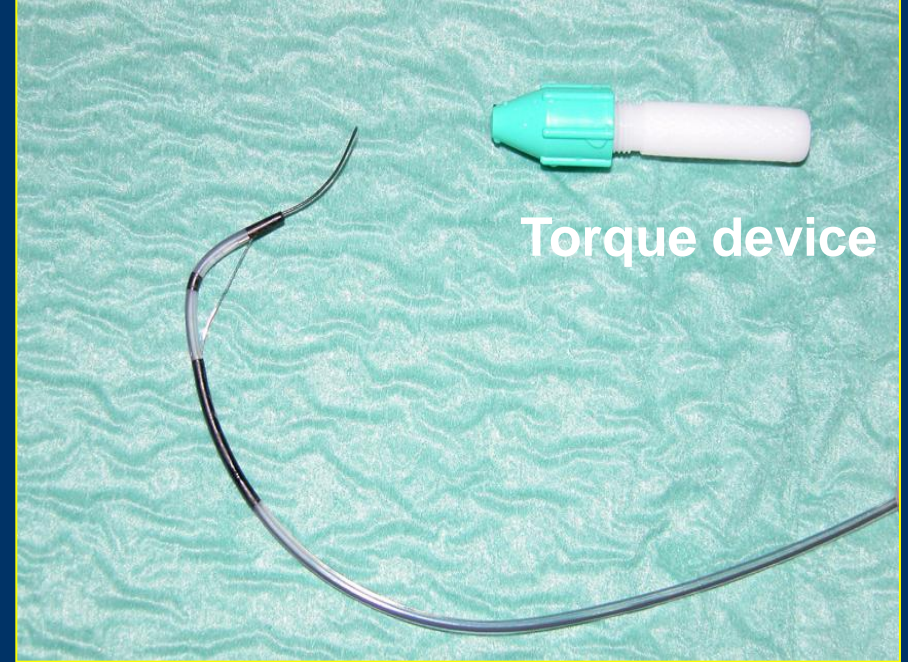
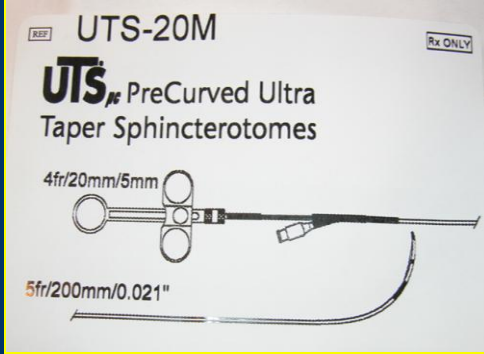


Tricks for cannulation

- Semi-long loop for access, short for treatment
- Secretin (with methylen blue) to see the orifice
- Tapered cannula or 0.20 GW cannulation
- Sphincterotomy or over the stent precut

Early chronic pancreatitis and PD





STIFF TYPE

ANGLED

GUIDE WIRE DIAMETER / DIAMETRE DU GUIDE: 0.020" (0.51mm)
 DURCHMESSER / DIAMETRO GUIA:
 DIAMETRO DELLA GUIDA:
 VOERDRAAD / DIAMETRO:
 GUIDE WIRE DIAMETER:

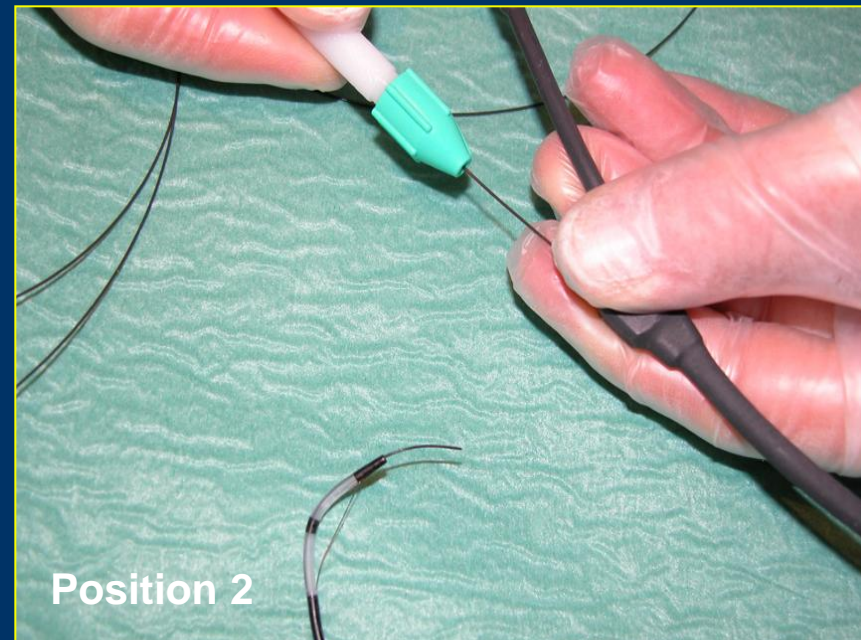
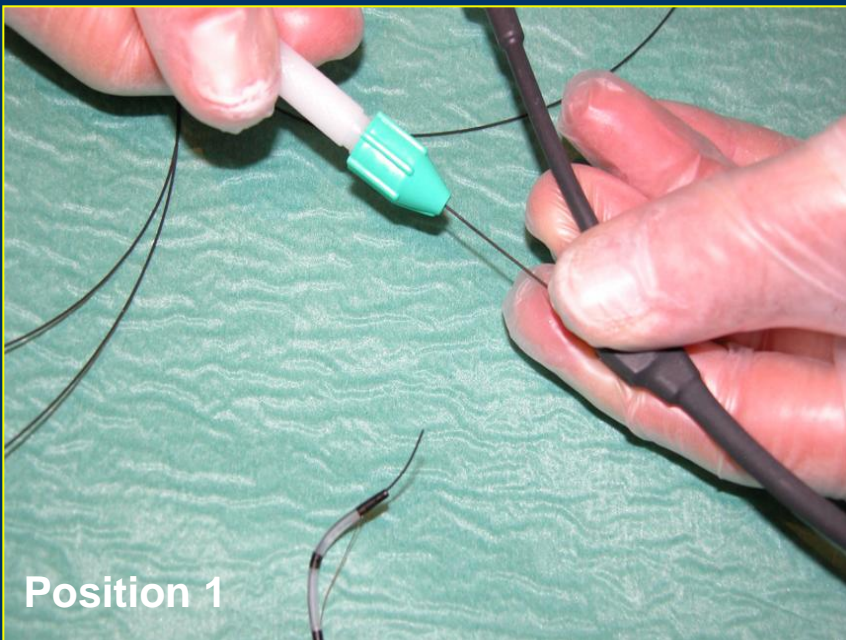
LENGTH / LONGUEUR: 450cm
 LONGUEUR DE L'EXTREMITÉ FLEXIBLE: 3cm
 LANGE / LONGITUD: 450cm
 LANGE DER FLEXIBLEN SPITZE: 3cm
 LUNGHEZZA: 450cm
 LUNGHEZZA DELLA PARTE FLESSIBILE: 3cm
 LENGTE / LANGD: 450cm
 BOUJIG SPETS LANGD: 3cm

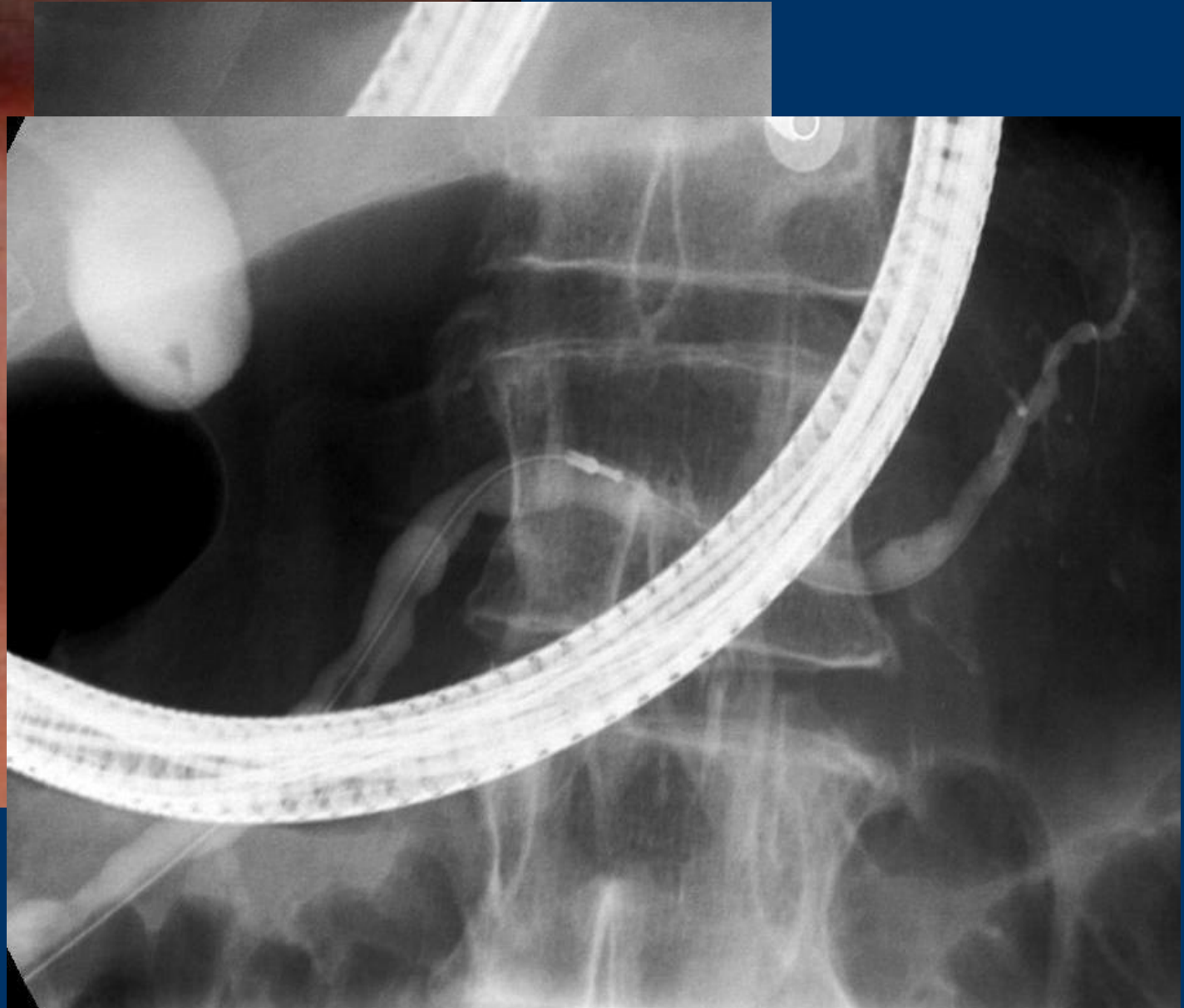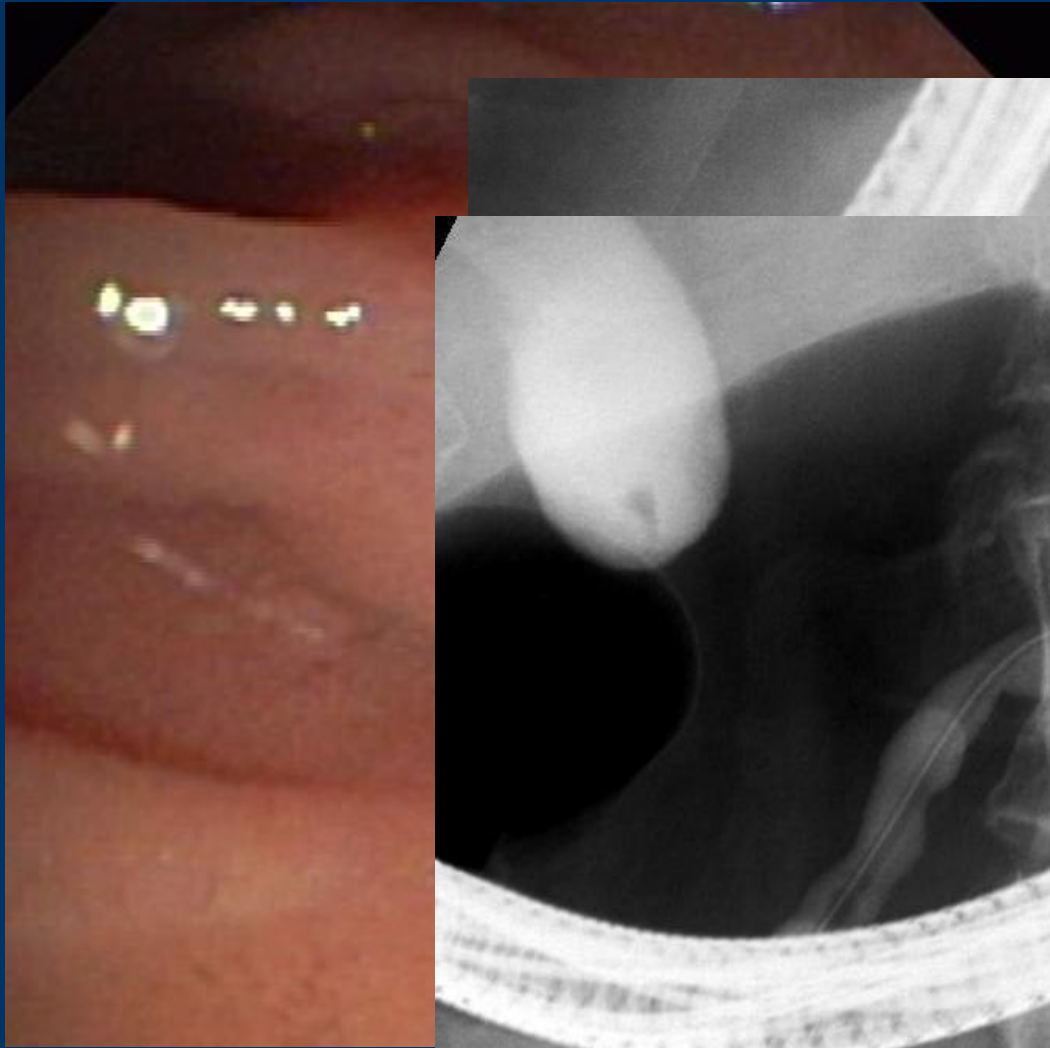
LOT : 0301046 ⏰ : 2004-12

Manufactured by: Fabriqué par: Hergestellt von: Fabricado por:
 Prodotto da: Vervaardigd door: Tillverkas av: **TERUMO EUROPE N.V.** 3001 LEUVEN, BELGIUM
 Manufactured under the licence of TERUMO CORPORATION.

(01)05413206007165

(20)00(17)041231(10)03010





GEEW

28th European Workshop

June 21-23, 2010

Brussels

www.live-endoscopy.com

